

---

## OPTICAL COHERENCE TOMOGRAPHY

---

Dr Kamal Nagpal, MS, DO; Dr Manish Nagpal, MS, DO, FRCS (UK);  
Dr Narendra GV, MS; Dr PN Nagpal, MS, FACS

Optical coherence tomography (OCT) is an optical technique for high resolution, cross-sectional imaging of tissue. It is analogous to computed tomography, which uses X rays, magnetic resonance, which uses spin resonance and ultrasound B scan, which uses sound waves. OCT uses a superluminescent diode as its light source. It can perform micron resolution (< 10 microns) cross-sectional or tomographical imaging in biological tissues.

### Principle

OCT is based on the principles of low coherence interferometry. Low coherent superluminescent diode light is directed onto a partially reflective mirror (splitter), whereby two beams are created - measurement and reference beams. The measurement beam is directed into the subject's eye. Here it gets reflected from the boundaries between the microstructures and scattered differently from tissues with different optical properties. The reference beam is reflected from the reference mirror at a known, variable position. Both beams are combined resulting in a phenomenon called interference. This interference is measured by the means of a photosensitive detector. The echo time delay of the measurement and reference beams is compared. Several data points over 2 mm of depth are integrated by the interferometer to construct a tomogram of retinal structures. Image thus produced has an axial resolution of < 10 microns and a transverse resolution of 20 microns. The operating wavelength of OCT probe beam is typically in the near infrared (800 nm) and thus minimally visible to the patient.

The tomogram is displayed in either grey scale or false color on a high resolution computer screen. It allows measurement of retinal thickness from the tomograms by means of computer image-processing techniques. Diagnostic applications in ophthalmology are made easy because of simplicity of optical access to the anterior and posterior segments of the eye. These features help yield powerful diagnostic information, complementary to conventional fundus photography and fluorescein angiography. The scale of resolution in OCT provides an in vivo alternative to histopathology.

### Basis for interpretation of OCT images

The physical basis of imaging depends on the contrast in optical reflectivity between different tissue microstructures. The proportion of incident light which is directly back scattered by a tissue structure defines the reflectivity of that structure. The OCT signal from a tissue layer is a combination of its reflectivity and the absorption and scattering properties of the overlying layers. On this basis, cross-sectional images of reflectivity in tissues are obtained that can differentiate internal tissue structure.

### Applications

OCT permits simultaneous viewing of the position on the ocular structure being scanned as well as its transverse cross-section. It can be used either in real time to diagnose characteristic morphologies or to create a diagnostic record similar to fundus photography. The rapid acquisition time of OCT images permits many images to be acquired on different cross-sectional planes. Furthermore, OCT images contain quantitative information on dimensions of intraocular structures with the potential to stage disease progression or response to therapy. Its clinical applications can be summarized as:

- (a) Follow up of the clinical course, understanding the pathogenesis of the disease.
- (b) For assessing the response to medical /surgical/ laser therapy
- (c) For documentation and explaining the prognosis of a particular disease

These applications are valid for most disease processes affecting the posterior segment of the eye, and an endless discussion can ensue. However, we are providing a brief outline of the potential applications. For greater details readers are referred to the list of reading material, suggested at the end of this chapter.

### OCT imaging of normal anterior eye structures

The strongest reflected signals arise from epithelial surface of the cornea and the highly scattering sclera and the iris. Other clearly identifiable structure is

anterior capsule of lens. Structures in the angle region like trabecular meshwork and canal of Schlemm are not clearly visualized in the tomogram since the incident and backscattered light is highly attenuated after traversing the overlying scleral tissue.

### OCT imaging of normal retina

The optic nerve head can be identified on the basis of its contour – central depression of the cup and the stalk, behind being the anterior part of the nerve. The vitreous being non-reflective is seen as a dark space. The vitreo-retinal interface is demarcated by the contrast between the non-reflective vitreous and the backscattering surface of the retina. The inner margin of retina shows area of bright back scattering, a red layer that corresponding to the retinal nerve fiber layer (RNFL). Its thickness increases from the macula to the optic disc. A highly reflective red layer delineates the posterior boundary of the retina and corresponds to retinal pigment epithelia (RPE) and choriocapillaries. A dark layer indicative of minimal reflectivity appears just anterior to choriocapillaris layer and represents the outer segment of retinal photoreceptors. The intermediate layers exhibit moderate back scattering. Below choriocapillaries, relatively weak scattering returns from the deep choroid and sclera, due to attenuation of the signal after passing through the overlying layers. Fovea is identifiable by the characteristic thinning of the retinal layers.

### Tomograms at disc, peri-papillary region, including RNFL:

The points at which choriocapillaris terminates at lamina cribrosa determines the disc boundaries. Extrapolation of these points to retinal surface defines a line segment which measures disc diameter. Documentation of nerve fiber layer thickness and degeneration in the peripapillary region is important, apart from optic disc cupping, in diagnosis and treatment of glaucoma and other neurodegenerative diseases. The RNFL in peripapillary region is assessed by imaging the cylindrical tissue sections centered around optic disc. The RNFL, RPE/choriocapillaris in peripapillary region are imaged as highly backscattering anterior and posterior layers respectively. The inferotemporal and supertemporal nerve fiber bundles are evident in both tomograms as localized thickenings in both the RNFL and retina. The observation of depressions from both anterior and

posterior margins is a helpful indicator of RNFL thinning.

### Retinal Thickness

OCT is uniquely suited for measurement retinal thickness - an important parameter in assessment of macular diseases by virtue of high axial resolution combined with well defined contrasts in reflectivity at the anterior and posterior boundaries of retina. Retinal edema causes increased retinal thickness and a change in the scattering properties of the tissue. Retinal edema may be differentiated from retinal traction by identification of cystic spaces within the retina or by the visualization of posterior hyaloid or epiretinal membrane causing traction. Decreased retinal thickness occurs with atrophy or scarring and may be either focal or diffuse.

### Interpretation of abnormal OCT imaging

Reflectivity pattern of the scanned images is used to interpret abnormal findings as follows:

- **Hyper-reflectivity:** Can be caused by inflammatory infiltrate into any layer of retina, fibrosis like disciform or other scar, hard exudates, and hemorrhages. Thin hemorrhages appear as thin, highly reflective bands with little effect on underlying tissue. Thick hemorrhages completely attenuate reflections from underlying structures.
- **Hypo-reflectivity:** Decreased reflectivity may be caused by retinal edema, serous fluid, hypopigmentation of RPE. These morphological causes of reduced back scattering must be distinguished from alterations in the incident light caused by dense cataracts, cloudy media, astigmatism, decentred lens implant or poor alignment of OCT instrument at imaging.
- **Nature of fluid:** Distinction between blood, serous fluid and exudate is made on the basis of reflectivity. Serous fluid is optically transparent, blood has both enhanced reflectivity and increased attenuation of the incident light. Exudate typically has intermediate appearance between blood and serous fluid on OCT images.
- **Detachments of neurosensory retina and RPE:** OCT is extremely useful for evaluating detachments of neurosensory retina and RPE. Neurosensory detachment appears as a shallow

elevation of the retina, with an optically clear space between the retina and RPE. The backscattering from the normally minimally reflective photoreceptors is increased, resulting in a well defined fluid-retina boundary. On the other hand, serous detachments of pigment epithelium show the reflective band corresponding to the RPE focally elevated over an optically clear space. The detached RPE is more reflective than normal, perhaps due to a refractive index difference between serous fluid and the choriocapillaris or due to decompensation and morphological changes in the RPE cells themselves. The angle of detachment is also more acute in a pigment epithelial to a neurosensory detachment, because of the tight adherence of RPE cells to the basement membrane at the edge of the detachment, which supports an increased fluid pressure.

#### OCT Methodology:

OCT imaging employs software that allows customized cross sectional optical cut sections to suit to a particular subject for the disease under study.

Thus, for macular disorders the following protocols may be applied:

1. Fast macular scan
2. Macular scan
3. Line scan
4. Repeat scan
5. Raster lines scan
6. Macular thickness scan
7. X-line scan

For studying glaucoma, the following protocols may be applied:

1. Optic disc scan
2. Concentric 3 rings scan
3. Nerve head circle scan
4. Fast optic disc scan
5. RNFL map scan
6. RNFL thickness scan
7. Fast RNFL thickness scan

8. Proportional circle scan
9. Radial lines scan
10. Cross hair scan

#### OCT IN MACULAR DISEASES

· **Macular hole and Vitreomacular traction:** OCT can effectively distinguish lesions that ophthalmoscopically resemble various stages of macular hole development like lamellar macular hole, macular cysts, foveal detachments of neurosensory retina or pigment epithelium, and epiretinal membranes with macular pseudoholes. It also effectively stages idiopathic macular holes according to the criteria developed by GASS, which may be important in evaluating surgical intervention. **Stage 1**, impending macular holes may be distinguished by a reduced or absent foveal pit and presence of optically clear space beneath fovea suggestive of foveolar detachment. **Stage 2** holes have an attached operculum corresponding to a partial break in the outer retinal tissue. A full thickness retinal dehiscence with a complete break in the outer retinal tissue and variable amounts of surrounding macular edema is observed in **Stage 3** hole. An operculum may be present and is completely separated from edges of the hole. **Stage 4** holes are characterized by complete loss of tissue and a detachment of the posterior hyaloid involving the fovea and optic disc.

Vitreomacular traction has been implicated in the pathogenesis of hole formation. OCT can assess the status of vitreoretinal interface which is useful in evaluating the risk of hole formation, especially in the fellow eyes of patients with a unilateral macular hole. Vitreous detachment has a protective value in preventing hole formation. OCT tomograms identify a detached vitreous by presence of a faint membrane anterior to the retina corresponding to the posterior hyaloid. Fellow eyes with a high risk of progression to a full thickness hole display a perifoveal vitreous detachment with foveal adhesion and loss of normal pit contour. This heralds the onset of stage 1 hole and emphasizes the role of vitreous traction. With OCT tomograms, quantitative information may be directly extracted including – diameter of hole, the extent of surrounding subretinal fluid accumulation.

· **Epiretinal macular membranes:** OCT images confirms the diagnosis of faint, diaphanous

membranes and provides a cross sectional assessment of factors contributing to vision loss, such as membrane opacity, retinal distortion or tractional detachment and macular oedema. The thickness and reflectivity of membrane on tomogram gives information on membrane opacity. It has a higher reflectivity than underlying retinal tissue and more thickness and differences in contour than detached posterior hyaloid. A macular pseudohole associated with an epimacular membrane displays a steepened foveal pit contour on OCT, simulating a full thickness hole but without a full thickness retinal dehiscence.

#### ● Retinal vascular disorders

**Retinal venous occlusions (BRVO/CRVO):** The OCT image findings include macular thickening, intraretinal fluid accumulation, serous retinal detachment, cystoid macular edema, lamellar macular hole formation and papilledema. OCT is useful in quantitatively monitoring the development of macular edema and its resolution following treatment.

Macular thickening due to BRVO with chronic macular edema and ischemic CRVO may be measured at one or many points on identically placed tomograms to accurately track the intraretinal or subretinal fluid accumulation with high resolution. OCT is valuable in evaluating the presence of serous retinal detachment secondary to a branch vein occlusion, seen as hyporeflexive intraretinal cavities in cross sectional scans radiating from the center of macula. It can demonstrate optic disc traction syndrome (vitreopapillary traction) associated with central retinal vein occlusion, due to traction from detached posterior hyaloid or from vitreopapillary membrane.

**Retinal arterial occlusion (CRAO):** Cases of CRAO exhibit acute macular edema followed by retinal atrophy, both of which may be assessed quantitatively on OCT by measurements of retinal thickness. The retinal pallor that accompanies ischemic retinal injury is visible on the OCT tomograms as enhanced reflectivity from the retinal nerve fiber layer and inner neurosensory retina.

#### ● Diabetic Retinopathy

**Macular edema is a leading cause of treatable vision loss in patients with diabetic retinopathy. OCT is effective in quantifying macular thickness. Measurements of central foveal thickness with**

**OCT correlate with visual acuity and provide indication of relative contribution of macular edema. Sequential tomograms allow accurately tracking changes in retinal thickness. Macular edema is seen as decreased intra-retinal reflectivity corresponding to cystic changes and fluid accumulation; and reduced back scattering obvious in outer retinal layers. Lamellar macular hole may form due to chronic cystoid macular edema, evident as partial thickness loss of retinal tissue and abnormal retinal contour suggesting cystic rupture. Hard exudates are seen as focal area of high intraretinal backscatter and complete shadowing of reflection from neurosensory retina. Cotton wool spots appear as regions of increased reflectivity of retinal fiber layer and inner neurosensory retina. Preretinal membranes in proliferative diabetic retinopathy are visible as thin, reflective bands anterior to the retina; traction can also be quantified. OCT has excellent reproducibility and is able to detect sight threatening macular edema with great reliability.**

#### Defining the disease Pattern

By conventional techniques of retinal examination, we see diabetic macular edema as a two dimensional pathology. The OCT almost gives the in vivo histopathology of the retinal layers that helps in the better understanding and pathogenesis of the disease process. OCT is a useful tool in monitoring response to an intervention in clinically significant macular edema (CSME).

Diabetic macular edema has been found to have 5 distinct OCT patterns:

- Sponge-like retinal thickness
- Cystoid macular edema
- Subfoveal serous retinal detachment
- Foveal tractional retinal detachment
- Taut posterior hyaloid membrane

OCT findings, which mostly complement fluorescein angiography may have a role towards indicating treatment of diabetic macular edema. Pattern 1, i.e. sponge like thickening can be considered an indication for focal/grid laser photocoagulation. Pattern 2, i.e.

cystoid macular edema shows good response to intravitreal triamcinolone injection, where OCT also helps in close monitoring following the injection. Pattern 3, i.e. subfoveal serous retinal detachment could be laser induced or caused by associated traction, the latter being an indication for vitrectomy. Patterns 4 and 5, i.e. tractional foveal detachment and taut posterior hyaloid membrane (TPHM) either alone or in conjunction with patterns 2 and 3 constitute an indication for surgical intervention.

• **Central Serous Retinopathy (CSR):** Longitudinal examinations with OCT are able to track the resolution of small elevations of neurosensory retina because of clear difference in optical reflectivity between retinal tissue and serous fluid. OCT differentiates CSR from occult form of choroidal neovascularisation which may show similar angiographic appearance when a focal leakage point is present. Neurosensory detachments exhibit well defined reflection at fluid-RPE interface, whereas elevation of RPE reflection above an optically clear space occurs when the pigment epithelium is detached (PED).

● **Age Related Macular Degeneration (ARMD):** OCT can cross sectionally image the morphological changes in non exudative ARMD and aids in the diagnosis and management of exudative ARMD. Many eyes with choroidal neovascularisation lack the fluorescein angiographic features required for treatment eligibility according to macular photocoagulation study guidelines. OCT may represent a new technique for visualizing angiographically occult CNV. OCT is effective in identification and quantification of subretinal, intraretinal and sub-RPE fluid and is particularly useful in evaluating possible foveal involvement of fluid collection. Retinal thickness measurement by OCT provides objective means of following edema and subretinal fluid in a patient through successive examination. OCT detects occult membranes, identifies type I & II membranes, and detects various types of PED – serous, hemorrhagic and fibrovascular. In brief, the appearance of tomogram in the following conditions is given:

**1. Soft drusen** – Mild back scatter extending from RPE to choroids

**2. Geographic atrophy-** Increased choroidal signals, thin retina

**3. Sub-retinal neovascular membrane (SRNVM)**

- Fragmentation and thickening of posterior reflection and may be associated with thickening of neurosensory retina

**4. RPE hyperpigmentation-** Increased reflectivity, shadowing of backscattering from choroid

**5. Pigment epithelial detachment (PED)** - serous detachments have clear cavity with focally elevated reflective band corresponding to RPE over it; while hemorrhagic detachment have brighter back scatter

**6. Classic SRNVM-** Definite boundaries and localized disruption or fusiform thickening of RPE / chorocapillaris complex

**7. Occult SRNVM-** Fibrovascular PED:

8. Well defined elevation of RPE with mild back scattering due to fibrous proliferation; no shadowing of choroidal reflection- similar to soft drusen, unlike serous or haemorrhagic PED

**9. Disciform scar-** Like laser scars, they appear on OCT as highly reflective and well demarcated lesions at the chorioretinal interface.

• **Chorioretinal Inflammatory Diseases:** OCT can provide dynamic images of the inflammatory process, localizing the infiltrate to specific retinal layers and providing a means to track the extent of inflammation following treatment. Vision loss in uveitis due to macular edema can be followed with tomograms in assessment of retinal thickness. OCT is useful in assessing the density of infiltrate, the morphological changes like edema, and atrophy. OCT image in inflammation shows increase in reflectivity as the inflammatory cells scatter the rays. In a case of sympathetic ophthalmitis and Vogt-Koyanagi-Harada syndromes, OCT scans reveal increased retinal thickness comprising of multiple sub-sensory retinal cystic spaces. A course of pulse intravenous methyl prednisolone therapy in a case of sympathetic ophthalmitis shows remarkable diminution the edema and serous detachments. Premature termination of treatment (oral steroids) may precipitate a recurrence. Thus monitoring on OCT over a period of time may be useful in guiding the treatment endpoint.

**Limitations**

Presence of conditions like asteroid hyalosis, cloudy media, high astigmatism, decentred lens implant and

dense cataracts can compromise the quality of the tomograms.

### Suggested reading

1. Michael Jumper, Features of Macular hole closure in the early postoperative period using optical coherence tomography. *Retina*.20: 232-237, 2000
2. Gupta V, Gupta A, Dogra MR. Inflammatory diseases of retina-choroid. In *Atlas Optical Coherence Tomography of Macular Diseases*, Jaypee Bros. Med. Publishers (P) Ltd. 2004;241-52
3. Michael S, Brad J Baker, Anatomical Outcomes of Surgery for idiopathic macular hole as determined by OCT, *Arch Ophthalmol*-2002, 120:29-35
4. Michael N Apostolopoulos, Evaluation of Successful Macular hole surgery by OCT & Multifocal ERG. *Am J Ophthalmol* 2002, 134:667-674
5. V. Tanner. Optical coherence Tomography of the Vitreoretinal interface in macular hole formation. *Br J Ophthalmol* 2001, 85:1092-1097
6. Haruhiko Yamada. Spontaneous closure of Traumatic Macular hole; *Am J Ophthalmol* 2002; 134:340-347
7. Reika Sou. Optical coherence Tomographic evaluation of a surgically treated Traumatic macular hole secondary to Nd: Yag laser injury; *Am J Ophthalmol* 2003;135:537-539
8. Richard F Spaide. Optical Coherence Tomography of Branch retinal vein Occlusion; *Retina*, 23:343-347, 2003
9. Shimon Rumelt. Optic Disc Traction Syndrome associated with central Retinal vein Occlusion; *Arch Ophthalmol*.2003; 121:1093-1097
10. Antonio Polito. Comparision between Retinal thickness Analyser and OCT for assessment of foveal thickness in eyes with macular disease; *Am J Ophthalmol* 2002; 134:240-251
11. Isabel Pires. Retinal thickness in eyes with mild NPDR in patients with Type 2 Diabetes mellitus – comparision of Measurements obtained by retinal Thickness analysis and OCT; *Arch Ophthalmol* 2002; 120:1301-1306
12. Winfried Goebel. Retinal Thickness in Diabetic Retinopathy- Study using OCT; *Retina* –22:759-767,2002
13. Teiko Yamamoto. Early Postoperative Retinal Thickness changes and complications after Vitrectomy for Diabetic Macular oedema; *Am J Ophthalmol* 2003; 135:14-19
14. Pascale Massin. OCT for evaluating Diabetic Macular oedema before and after Vitrectomy; *Am J Ophthalmol* 135:169-177
15. Yumiko Yamaguchi. Resolution of Diabetic Cystoid Macular Edema associated with spontaneous vitreofoveal separation, *Am J Ophthalmol* 2003; 135:116-118
16. Carl H Park. Macular Translocation Surgery with 360-degree peripheral retinectomy following ocular photodynamic therapy of choroidal neovascularization; *Am J Ophthalmol* 2003; 136:830-835
17. T. Daniel Ting. Decreased Visual Acuity associated with cystoid Macular oedema in Neovascular Age Related Macular degeneration; *Arch Ophthalmol* 2002; 120:731-737
18. Lvisa Pierro. Optical coherence tomography findings in Adult onset foveomacular vitelliform dystrophy 2002; 134:675-680
19. Jose Garcia-Arumi. Vitreoretinal surgery for Cystoid Macular oedema associated with Retinitis Pigmentosa; *Ophthalmology*, 2003; 110:1164-1169
20. Wolfgang Drexler. Enhanced Visualization of Macular pathology with use of ultra high resolution OCT; *Arch Ophthal* 2003; 121:695-706
21. Richard J Antcliff. Comparision between OCT and FFA for detection of CME in uveitis patients; *Ophthalmology* 2000; 107:593-599
22. Norikazu Hagimura. OCT of the neurosensory retina in rhegmetagenous Retinal detachment, *Am J Ophthalmol* 2000; 129; 186-190

23. Norikaza Hajimura. Persistent foveal RD after successful Rhegmetogenous Retinal detachment Surgery, Am J Ophthalmol 2002;133:516-520
24. Takayuki Baba. Prevalance and characteristics of Foveal Retinal detachment without macular hole in high myopia; Am J Ophthalmol 2003; 135:338-342
25. Vincent J Hoye. OCT demonstrates subretinal macular edema from papilledema; Arch Ophthalmol; 2001; 119:1287-1290
26. Panagiotis G Theodossiadis. Retinal disorders in preeclampsia studied with OCT; Am J Ophthalmol 2002; 133:707-709
27. Alfonso Giovannini. OCT in the assessment of RPE tear; Retina 20:37-40; 2000
28. Naoichi Horio. Progressive change of optical coherence tomography scans in Retinal degeneration slow mice; Arch Ophthalmol 2001; 119:1329-1332.

**Contact Details****Corresponding author:****Dr Kamal Nagpal**

Address:

Retina foundation

Near Shahibag Underbridge,

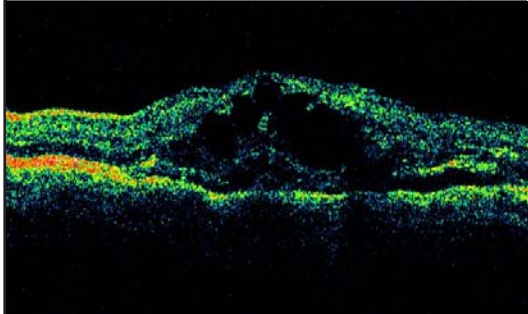
Rajbhavan Road,

Ahmedabad – 380 004.

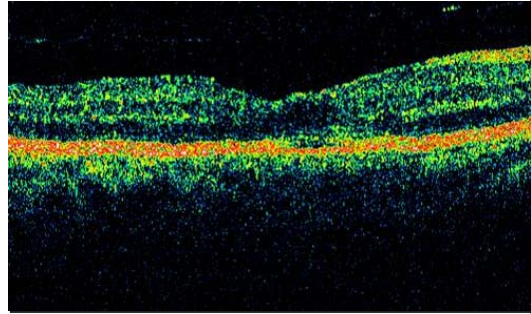
Tel:079-22865537, 22867982, Fax:91-079-22866381

Res:079-22865090, 22869531

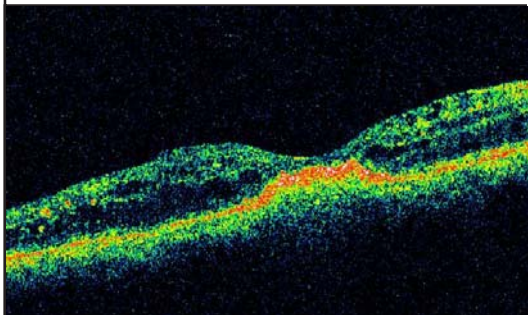
Email:manishad1@sancharnet.in



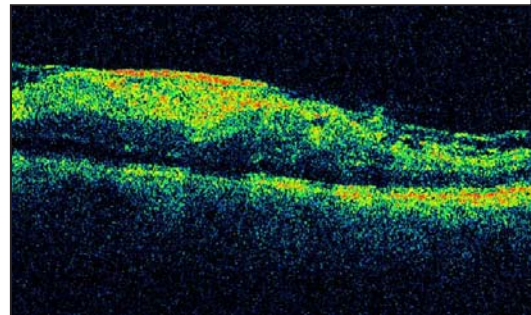
BRVO - OCT



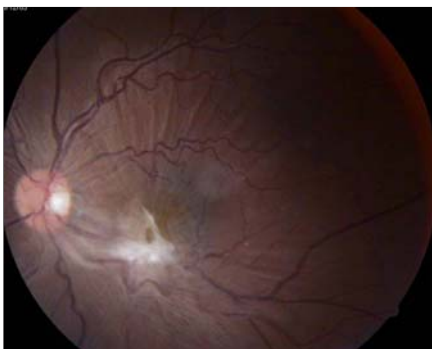CME - OCT



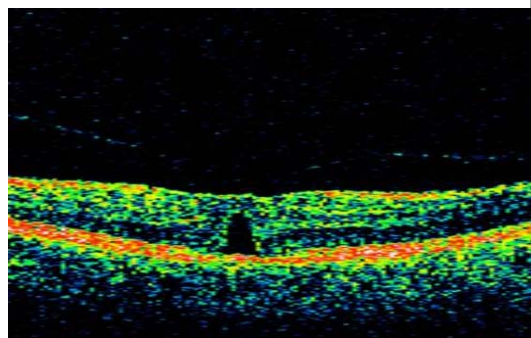
MACULOPATHY - OCT



ERM - OCT

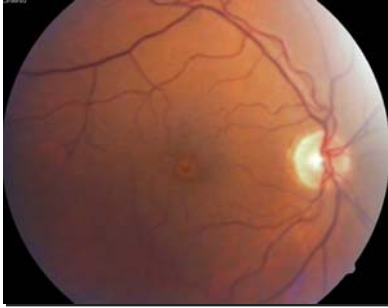

ERM - PHOTO

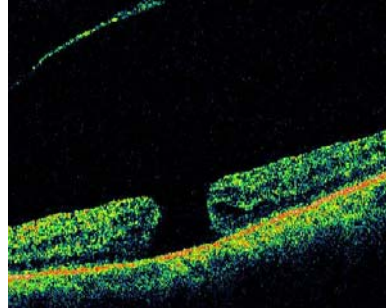


GRADE 2 MAC HOLE - OCT

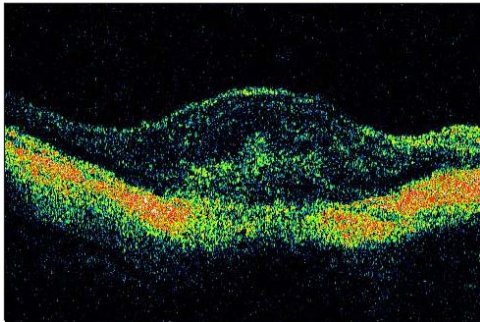




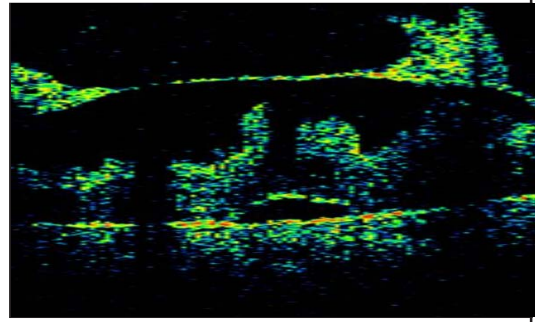
GRADE 2 MAC HOLE



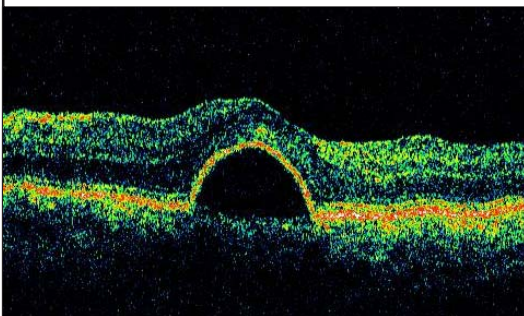
GRADE 4 MAC HOLE - OCT



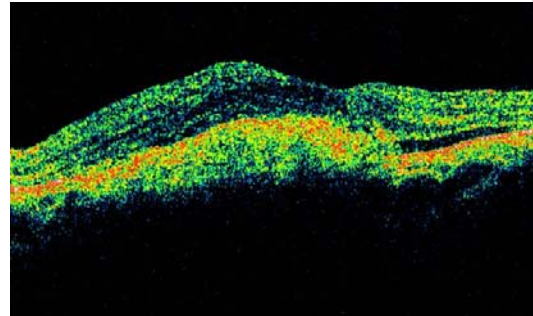
MYOPIC SRNV - OCT



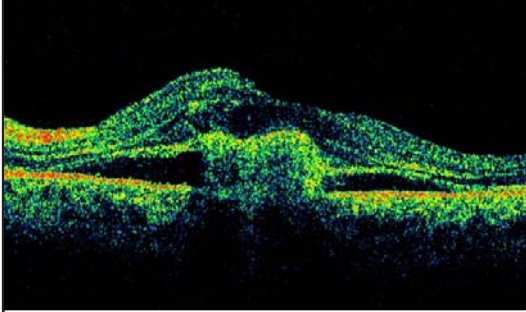
Pdr - OCT



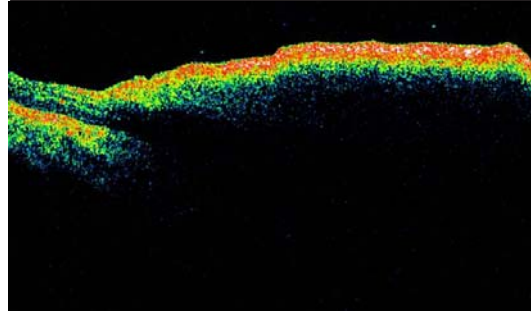
Ped - OCT



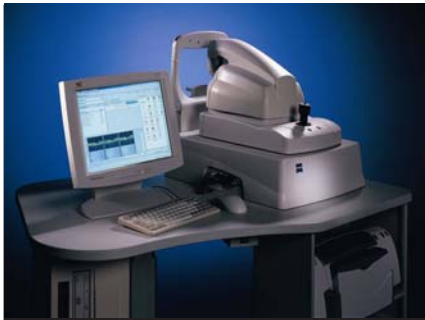
Srnvm - OCT



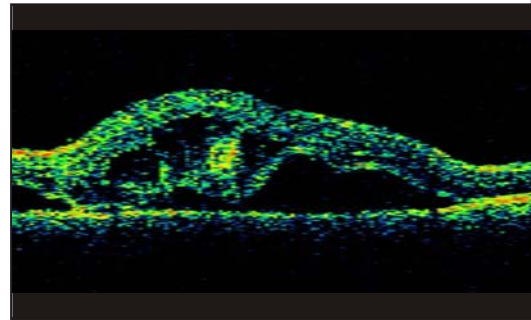
SRNV 2 - OCT



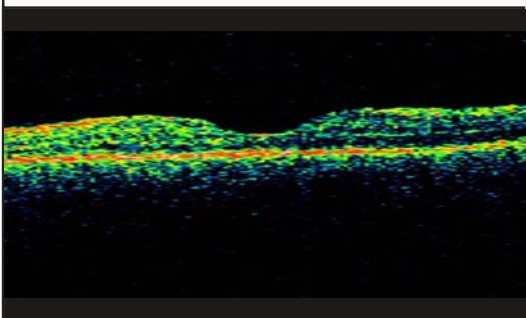
SHH PRE YAG HYALOIDECTOMY - OCT



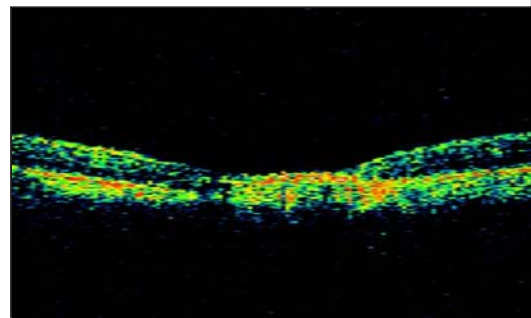
OCT MACHINE



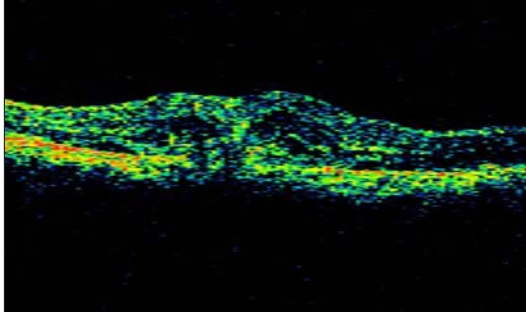
SYMPATHETIC OPHTHALMIA PRE TREATMENT - OCT



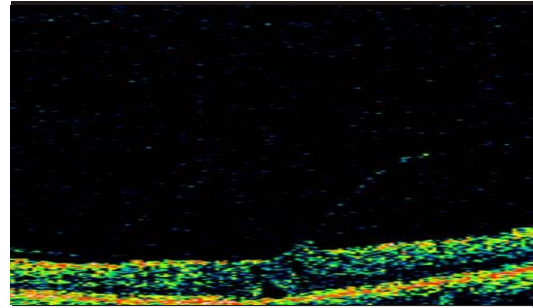
SYMPATHETIC OPHTHALMIA POST TREATMENT 2 WEEKS - OCT



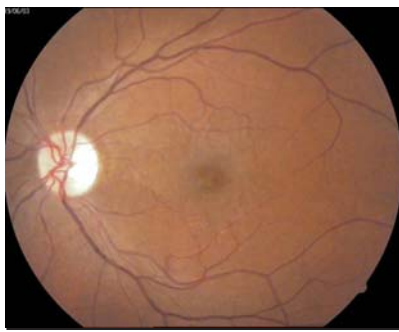POST TTT - OCT



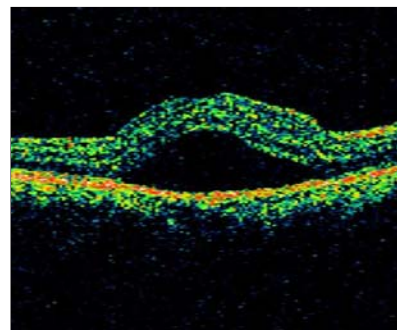
PRE TTT - OCT



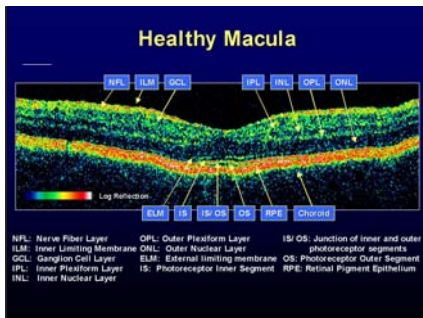
VITREO FOVEAL TRACTION - OCT



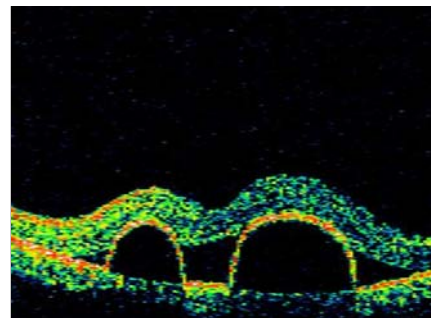
VITREO FOVEAL TRACTION - PHOTO



CSR - OCT



NORMAL - OCT



PED - OCT